

# MICROARTERIAL ANASTOMOSES USING THE DIODE LASER: LONG-TERM MORPHOLOGICAL RESULTS

Jing Tang,<sup>†</sup> Michel Prudhomme,<sup>†</sup> Simone Rouy,<sup>†</sup> Guilhem Godlewski,<sup>†</sup> Serge Ovtchinkoff,<sup>‡</sup> Guy Delacretaz,<sup>\*</sup> and René P. Salathé<sup>\*</sup>

<sup>†</sup>Montpellier I University, Faculty of Medicine Montpellier-Nîmes, Laboratory of Experimental Anatomy, F-30900 Nîmes, France; <sup>‡</sup>Hospital Gaston Doumergue, Department of Medical Imagery, F-30006 Nîmes, France; <sup>\*</sup>Ecole Polytechnique Fédérale, LOA, Department of Micro-Technique, Ecublens, CH-1015 Lausanne, Switzerland

(Paper JBO-005 received April 26, 1995; revised manuscript received Sep. 28, 1995; accepted for publication Oct. 1, 1995)

## ABSTRACT

In a series of 70 Wistar rats submitted to a noncontact diode laser-assisted carotid end-to-end anastomosis (LAMA) versus controlateral manual suture microanastomosis (CMA), contrast angiography and scanning electron microscopy were performed in a group of 18 animals at a long-term follow up of 7 months after operation. The investigation of angiography realized by means of a CGR General Electric DG 200 with a 512 digital matrix gave precise images of vessel wall repair and vessel patency. It permitted a simultaneous comparison between laser and manual anastomosis. Patency rate was 83% in LAMA and 78% in CMA. Nonlethal complications such as 1 stenosis, 2 thromboses in LAMA and 1 stenosis, 2 thromboses, and 1 pseudoaneurysm in CMA were observed. The results could be correlated to scanning electron microscopy findings and confirmed the morphological superiority of the laser technique.

**Key Words** diode laser; microarterial anastomosis; contrast angiography.

## 1 INTRODUCTION

Recently, diode laser has been used for microvascular repair.<sup>1-6</sup> Previous experimental studies have demonstrated the feasibility of laser assisted microvascular anastomosis (LAMA) with neodymium/yttrium-aluminum-garnet (Nd YAG), argon, or CO<sub>2</sub> laser systems.<sup>7-14</sup> Diode laser welding was first used experimentally in 1989 by Unno<sup>1</sup> and by Oz<sup>2</sup>, the former using a ceramic contact probe and the latter a focusing optical system applied to the anastomotic line stained by a chromophore. In a previous paper<sup>5</sup> we investigated the use of a noncontact diode laser system: the laser source, the anastomosis technique, Doppler spectral analysis, and light microscopy results at short follow-up (day 0 to day 30) were presented. The aim of this paper is to report findings obtained by contrast angiography and by scanning electron microscopy (SEM) at a long term follow-up (7 months).

## 2 MATERIALS AND METHODS

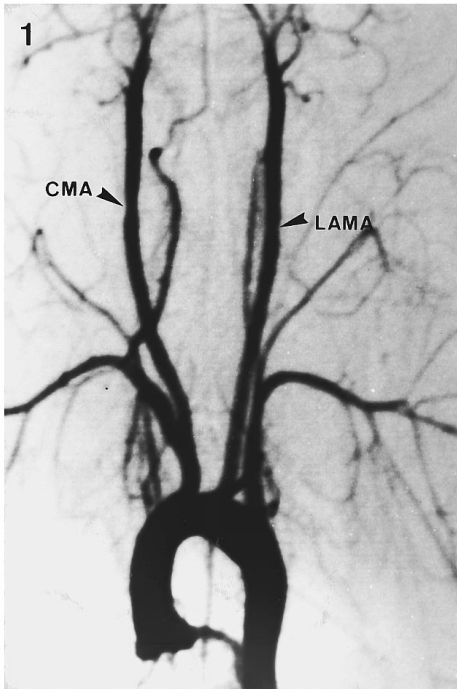
A series of 70 Wistar rats (weight range 280 to 420 g) was submitted to bilateral common carotid (0.8 to 1.2 mm in diameter) end-to-end anastomosis performed by means of a noncontact diode laser on the left side (LAMA) and by manual suture (CMA) on

the right. After neck cervicotomy, the left carotid was isolated and transected between two clamps. After placement of three 10.0 Ethilon stitches BV 70 (Ethnor, Neuilly, France) for edge coaptation, LAMA was achieved from the outside using three laser shots of 500 mW power, 4.5 s duration, and 700 W/cm<sup>2</sup> irradiance each. The apparatus was a 830-nm diode laser prototype (EPFL, Switzerland). The beam was focused to a 300- $\mu$ m diameter by a micromanipulator prototype coupled to a Zeiss OPM1 microscope. CMA was performed on the right carotid by means of six 10.0 stitches. Both anastomoses were carried out by the same operator in the same animal. The details of the technique have been reported elsewhere.<sup>5</sup> No retreatment was necessary.

The mean time for completing an anastomosis was 13 min in LAMA versus 22 min in CMA. Immediate patency of the anastomosis was determined by the empty and refill test, by intraoperative macroscopic examination, and by Doppler spectral analysis. As in our previous experience,<sup>10</sup> regular controls were maintained from day 0 to day 210. On day 210, 18 animals were submitted to contrast angiography and to scanning electron microscopy (SEM).

Contrast angiography was performed by means of a CGR General Electric DG 200 (CGR Society,

Address all correspondence to Guilhem Godlewski.



**Fig. 1** Contrast angiography on day 210. Both anastomoses are fully patent: LAMA is located on the left carotid, CMA on the right carotid. Arrows indicate the level of the anastomosis.

Issy-les-Moulineaux, France) with a 512 digital matrix and a 3.6 images/second system. The rats being anesthetized by ketamine (100 mg/kg), the angiography was realized through medial coeliotomy and abdominal aorta puncture. A 1-mm catheter (Endoflex, Laboratoire Pharmaceutique, Saint Leu-La-Forêt, France) was introduced in the anterior face of the aorta and radiologically guided and positioned up to the aortic arch. Contrast medium (2 to 3 cc) (Hexabrix 200, Guerbet Society, Aulnay sous Bois, France) was manually injected and digitalized arteriograms were obtained in all cases. After arteriography the rats were kept alive for final SEM. Samples for SEM were perfused with Ringers' solution and then opened longitudinally. Specimens were fixed in 2.5% glutaraldehyde and washed in cacodylate buffer (pH 7.4). After dehydration in graded alcohol, the samples were dried by the critical point drying method, covered with gold, and examined through a scanning electron microscope S 4000 (Hitachi, Tokyo, Japan).

The patency of the vessel, i.e., degree of stenosis or parietal alterations, was assessed with a calibrated magnifying eyepiece at the point of anastomosis and compared with that of a disease-free vessel segment above the lesion. The image was only obtained anteriorly. The degree of stenosis was evaluated as significant when the diameter of the anastomosis was less than 80% of the normal vessel diameter. The angiograms were interpreted in a "blind" fashion by three radiologists and the mea-

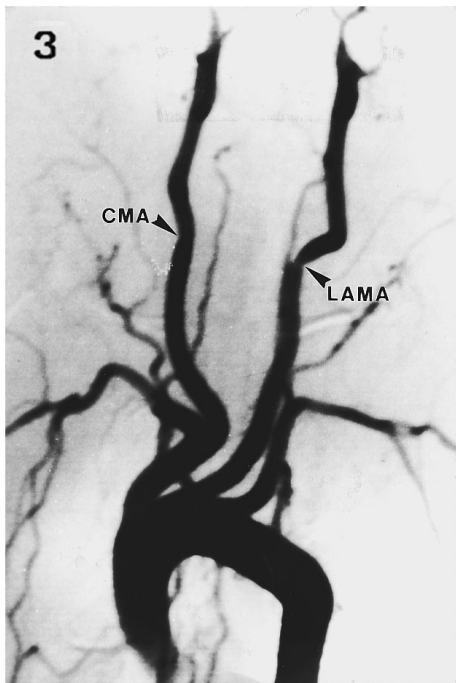


**Fig. 2** Scanning electron microscopy view of LAMA on day 210. The anastomosis line (AL) is quite indiscernible except by the presence of Ethilon stitches (ES) necessary for edge coaptation. The endothelial cells covering the sealing line are regularly reorganized along the axis of the blood flow. X 300.

surements compared. Testing for significance employed the chi-square test.

### 3 RESULTS

Seven months after the operation, the contrast angiography visualized the quality of the vessel wall repair and the vessel patency. After LAMA the vessel repair was excellent in 8 out of 18 carotids. The welding sites were indiscernible and the vascular flow quite normal (Fig. 1); 7 out of 18 carotid anastomoses were very satisfactory. Minor stenoses (less than 8%) identified as small parietal irregularities were found and did not alter the vessel patency. SEM confirmed in each case the good repair of the anastomotic site. The appearance of endothelial cells was quite normal (Fig. 2), the cells covering the sealing line being reorganized in the axis of the blood flow. In the media, a regular network of collagen bundles and elastic fibers occupied the healing site. Finally, the anastomosis site was no longer recognizable except in some cases by the presence of a smooth elevation of the surface due to medial repair, which probably also explains the minor parietal irregularities mentioned above. Only three serious complications were observed and related to the technique: 1 stenosis of 55% (Fig. 3) and 2 thromboses. After CMA, the vessel wall repair of the anastomotic line was satisfactory in 14 out of 18 carotids. In 4 cases major complications were present: 1 pseudoaneurysm, 1 stenosis (60%), and 2 thromboses. In the 14 satisfactory results, the anastomosis site was generally underlined by a small and obvious notch ( $n = 13$ ) indicating a slight degree of stenosis ( $\leq 19.7\%$ ) which was probably due to parietal folds or to a medial fibrotic ring of the suture line (Table 1). SEM confirmed the fibrotic reaction surrounding the Ethilon stitches as well as the irregularity of the endothelial surface occupied by a small sulcus and distorted by protruding sutures (Fig. 4).



**Fig. 3** Angiogram of common carotids on day 210, demonstrating a significant stenosis on the left carotid submitted to laser-assisted microanastomosis (LAMA). The right carotid is fully patent (CMA). Arrows indicate the level of the anastomosis.

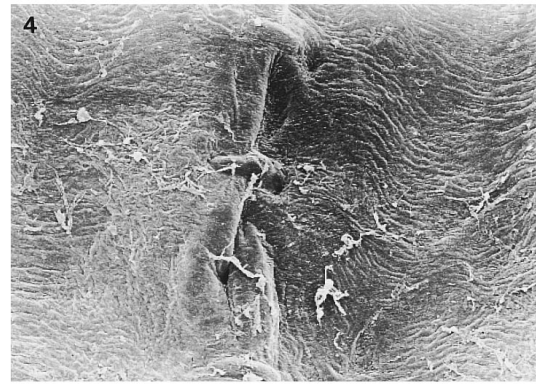
Finally from the standpoint of major complications, the patency rate (more than 80%) was 83% in LAMA and 78% in CMA (chi-square test,  $\chi^2 = 0.0565$ ,  $0.90 > P > 0.75$ ). In both anastomoses the incidence of these complications was comparable, with no significant difference. There were no lethal or neurological disorders, the cephalic blood flow being supplied by other carotid, vertebral arteries and the *circulus arteriosus* of Willis.

#### 4 DISCUSSION

This study demonstrated the usefulness of contrast angiography for long-term follow-up evaluation of the morphology and patency rate of laser assisted microanastomoses. The accuracy of this imaging

**Table 1** Experimental results in LAMA and CMA.

	LAMA (n=18)	CMA (n=18)
No stenoses	8	1
<10% stenoses	7	7
<20% stenoses	0	6
>50% stenoses	1	1
Thromboses	2	2
Pseudoaneurysm	0	1



**Fig. 4** Scanning electron microscopy view of CMA on day 210. The anastomosis line is underlined by a sulcus, protruding sutures, and endothelial folds due to pulling of the stitches. X 120.

technique is good enough to visualize the quality of wall repair, transanastomotic vascular flow, and the presence of possible complications. Nevertheless, coronal arteriography—which was only used in our experimental procedure to avoid superposition of carotid imaging—is limited in the acquisition of multiplanar information and tells the observer little about three-dimensional morphology or vessel wall characteristics. This could be obtained in the future by magnetic resonance angiography (MRA).<sup>15</sup>

The availability of laser and manual anastomosis in the same animal creates great interest in this type of imaging control because both anastomotic sites can be observed simultaneously. In our experience this invasive technique is an elegant one because the animals remain alive after examination and can be submitted to further investigation such as excision for scanning electron microscopy. It is difficult to compare our results with other laser techniques<sup>7-14</sup> using several different wavelengths and anastomosis procedures as well as other morphological controls. However, in our opinion, a noncontact technique using a micromanipulator instead of an optical fiber to direct the laser beam is performed in order to obtain more stable and more accurate irradiation. Up to now no similar angiography study dealing with long-term follow-up of LAMA has been reported.

In this series of LAMA (n = 18), the accuracy of this angiographic technique shows a patency rate of 83%. This rate is obviously less than the 93% success rate obtained elsewhere in short- and middle-term results.<sup>5</sup> In this work, the vessel wall modification and vessel patency were precisely identified by digitalized angiography whereas the intraoperative macroexamination, light microscopy, or transcutaneous Doppler spectral analysis used in the initial phase of the study<sup>5</sup> were less reliable. The contribution of angiographic results is that they could be directly correlated to the results of scanning electron microscopy. In LAMA the wall repair is excellent, the sealing line being entirely covered

by normal endothelial cells, while in CMA the medial wall and the endothelial surface were generally irregular with sulcus and folds caused by the pulling of stitches.<sup>5</sup>

Finally, in this comparative study the long-term patency rate is statistically comparable in both anastomoses (LAMA and CMA), with no significant difference in the number of complications. Nevertheless, the morphological superiority of LAMA in avoiding the distortion and fibrotic scar induced by CMA sutures must be pointed out.<sup>5</sup> In fact, operating speed remains the most important advantage of LAMA because it reduces the anastomotic time to 13 min versus 22 min for CMA and shortens the time of ischemia in reconstructive surgery.

Finally, the technical and financial advantages of diode lasers in comparison with other lasers must be emphasized. The device is of small size, light weight, and does not require a cooling system or special maintenance. The cost of actual diode systems is still a drawback but the price will decrease with the standardization of the technique.

Good vessel wall repair and shorter operating time with a low incidence of complications are important advantages of noncontact diode LAMA. The small size and technical simplicity of the device argues for its frequent use in microsurgery.

## REFERENCES

1. N. Unno, S. Sakaguchi, and K. Koyano, "Microvascular anastomosis using a new diode laser system with a contact probe," *Lasers Surg. Med.* **9**, 160-168 (1989).
2. Mc. Oz, R.S. Chuck, J.P. Johnson, S. Parangi, L.S. Bass, R. Nowygrod, and M.R. Treat, "Indocyanine green dye-enhanced welding with a diode laser," *Surg. Forum* **40**, 316-318 (1989).
3. Mc. Oz, L.S. Bass, R.S. Chuck, J.P. Johnson, S. Parangi, R. Nowygrod, and M.R. Treat, "Strength of laser vascular fusion: Preliminary observations on the role of thrombus," *Lasers Surg. Med.* **10**, 393-395 (1990).
4. G. Godlewski, J.M. Frapier, B. De Balmann, H. Mouzayek, S. Rouy, J. Tang, F. Weibel, J.M. Juan, and M. Dauzat, "Diode laser and microvascular carotid anastomosis: A preliminary study," *Lasers Med. Sci.* **8**, 33-38 (1993).
5. J. Tang, G. Godlewski, S. Rouy, M. Dauzat, J.M. Juan, F. Chambettaz, and R.P. Salathé, "Microarterial anastomosis using a noncontact diode laser vs a control study," *Lasers Surg. Med.* **14**, 229-237 (1994).
6. U.M. Reali, R. Gelli, V. Giannotti, F. Gori, R. Pratesi, and R. Pini, "Experimental diode laser-assisted microvascular anastomosis," *J. Reconstr. Microsurg.* **9**, 203 (1993).
7. K.K. Jain and W. Gorisch, "Repair of small blood vessels with the neodymium-YAG laser: A preliminary report," *Surgery (St. Louis)* **85**, 684-688 (1979).
8. K.H. Niiijima, Y. Yonekawa, H. Handa, and W. Taki, "Non-suture microvascular anastomosis using a Nd-YAG laser and watersoluble polyvinyl alcohol splint," *J. Neurosurgery* **67**, 579-583 (1989).
9. R.R. Krueger and E.E. Almquist, "Argon laser coagulation of blood for the anastomosis of small vessels," *Lasers Surg. Med.* **5**, 55-60 (1985).
10. G. Godlewski, P. Pradal, S. Rouy, A. Charras, M. Dauzat, O. Lan, and F.M. Lopez, "Microvascular carotid end-to-end anastomosis with the argon laser," *World J. Surg.* **10**, 829-833 (1986).
11. R.A. White, G. Kopchok, C. Donayre, R. Lyons, G. White, S.R. Klein, V.D. Pizzurro, R.P. Abergel, R.M. Dwyer, and J. Uitto, "Large vessel sealing with the argon laser," *Lasers Surg. Med.* **7**, 229-235 (1987).
12. A. Serure, E. H. Withers, S. Thomsen, and J. Morris, "Comparison of carbon dioxide laser-assisted microvascular anastomosis and conventional microvascular suture anastomosis," *Surg. Forum*; **34**;634-636 (1983).
13. A. Ruiz Razura, G.S. Branfman, M. Lan, and B.E. Cohen, "Laser-assisted microsurgical anastomosis in traumatized blood vessels," *J. Reconstr. Microsurg.* **6**;55 (1990).
14. C.R. Neblett, J.R. Morris, and S. Thomsen, "Laser-assisted microsurgical anastomosis," *Neurosurgery* **19**, 914 (1986).
15. S.M. Hertz, R.A. Baum, R.S. Owen, G.A. Holland, D.R. Logan, and J.P. Carpenter, "Comparison of magnetic resonance angiography and contrast angiography in peripheral arterial stenosis," *Am. J. Surg.* **166**, 112-116 (1993).